

## An Exceptional Case of Incomplete Abortion

P.L. Tripathy

Kishori Nursing Home, Bargarh (Orissa) 768028

Mrs. P. Rana, P<sub>2</sub>, aged about 32 years, presented with the complaints of passing small chips of bones per vagina infrequently for last 14-15 months.

She was treated for this complaint at various places with no relief. Rather she was stamped as a neurotic patient and was referred for psychiatric consultation. Her menstruation was regular 2-3 days/30-32 days. She had even undergone D & C in a dispensary/P.H.C. earlier about 6 months back for the same complaint. On taking her history in details she revealed that she had undergone uneventful MTP in a P.H.C. 1 ½ years back, of 14 weeks of pregnancy (by Dilatation & Evacuation method) and 3-4 months after the evacuation she noticed passing small chips of bones.

**On Examination:** She was of 49 kgs. Wt., Pulse-86 per minute, Normal Temperature – Normal BP-120/70 of Hg. Her Chest & Heart was normal. Per Abdominal examination revealed nothing suggestive.

**P/V Examination:** Uterus of normal size, firm in consistency, mobile, cervix & Vagina -Healthy.

Fornices Free – No vaginal discharge, os was closed, Cx-thick.

**USG-Findings:** Normal Endometrial texture

- Normal Uterine size
- Normal Adnexae
- Uterine Cavity showing small multiple hyperechoic bodies casting internal acoustic shadows.

**Pt was scheduled for:** EU/A & D & C

On thoroughly curetting the uterine cavity multiple small pieces of bones & cartilages were removed, which were almost in a organized state with the uterine wall.

Thereafter she recovered uneventfully & passed no more bone chips.

USG showed no hyperchoic bodies. (Photograph showing the bone chips removed during D & C (Fig. 1).

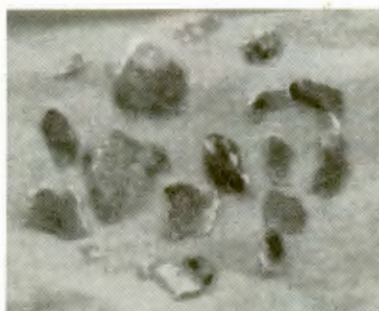


Fig. 1: Bone Chips removed during D & C